

Pars Planitis: Epidemiology, Clinical Characteristics, Management and Visual Prognosis

Pinar Cakar Ozdal¹, MD; Nilufer Berker¹, MD; Ilknur Tugal-Tutkun², MD

¹Service of Uveitis and Retinal Diseases, Ankara Ulucanlar Eye Research Hospital, Ankara, Turkey

²Department of Ophthalmology, Istanbul University Faculty of Medicine, Istanbul, Turkey

Abstract

Pars planitis is an idiopathic chronic intermediate uveitis which predominantly affects children and adolescents, and accounts for 5-26.7% of pediatric uveitis. Although an autoimmune process with a genetic predisposition has been suggested, its etiology still remains unknown. The most common presenting symptoms are floaters and blurred vision. Diffuse vitreous cells, haze, snowballs and snowbanks are typical findings of pars planitis. Peripheral retinal vasculitis, optic disc edema and anterior segment inflammation are other well-known findings. Although pars planitis is known to be a benign form of uveitis in most cases, it may become a potentially blinding disease due to complications including cataract, cystoid macular edema, vitreous opacities and optic disc edema. Cystoid macular edema is the most common cause of visual morbidity. Band keratopathy, epiretinal membrane formation, vitreous condensation, neovascularizations, vitreous hemorrhage, retinal detachment, cyclitic membranes, glaucoma and amblyopia may develop as a consequence of the chronic course of the disease. Exclusion of infectious and non-infectious causes which may present with intermediate uveitis is of utmost importance before starting treatment. Treatment of pars planitis has been a controversial issue. There is no consensus specifically for treatment of cases with minimal inflammation and relatively good visual acuity. However, current experience shows that pars planitis may cause severe inflammation and needs an aggressive treatment. A step ladder approach including corticosteroids, immunosuppressive agents, anti-tumor necrosis factor-alpha and pars plana vitrectomy and/or laser photocoagulation is the most commonly used method for treatment of pars planitis. Adequate control of inflammation and prompt detection of associated complications are crucial in order to improve the overall prognosis of the disease.

Keywords: Differential Diagnosis; Immunosuppressive Therapy; Intermediate Uveitis; Pars Planitis; Pediatric Uveitis

J Ophthalmic Vis Res 2015; 10 (4): 469-480.

INTRODUCTION

Pars planitis is an idiopathic chronic intermediate uveitis which predominantly affects children and

Correspondence to:

Ilknur Tugal-Tutkun, MD. Istanbul Tıp Fakültesi,
Göz Hastalıkları A.D. Capa, 34390 Istanbul, Turkey.
E-mail: itutkun@istanbul.edu.tr

Received: 22-07-2015


Accepted: 10-08-2015

adolescents. The term "intermediate uveitis" describes inflammation of the anterior vitreous, ciliary body and peripheral retina which may or may not be associated with infection or systemic disease, whereas the term "pars planitis" has been recommended for a particular subset of intermediate uveitis associated with snowbank and snowball formation in the absence of an infectious or systemic disease.¹¹

This is an open access article distributed under the terms of the Creative Commons Attribution-NonCommercial-ShareAlike 3.0 License, which allows others to remix, tweak, and build upon the work non-commercially, as long as the author is credited and the new creations are licensed under the identical terms.

For reprints contact: reprints@medknow.com

How to cite this article: Ozdal PC, Berker N, Tugal-Tutkun I. Pars planitis: Epidemiology, clinical characteristics, management and visual prognosis. *J Ophthalmic Vis Res* 2015;10:469-80.

Access this article online	
Quick Response Code: 	Website: www.jovr.org
	DOI: 10.4103/2008-322X.176397

EPIDEMIOLOGY AND ETIOLOGY

Most cases of intermediate uveitis in children exist without underlying disease, therefore they are classified as idiopathic intermediate uveitis or pars planitis.^{2,3} The incidence and prevalence of the disease show great variability according to geographic, genetic and referral patterns of the patients. Its yearly incidence has been reported to be 1.4 - 2 cases per 100,000 population in studies conducted in France and United States (US).⁴⁻⁶ Pars planitis accounts for 5 -26.7% of pediatric uveitis in different series.⁷⁻¹² In a retrospective study, Ozdal et al observed pars planitis as the leading cause of pediatric uveitis with a rate of 24%.¹¹ Whereas Soyulu et al, Smith et al, and Rosenberg et al reported slightly lower prevalence rates for pars planitis (8.9%, 17.1%, and 14.9%, respectively).³⁻¹⁰ Soyulu et al reported that pars planitis was the third most common cause of uveitis in Turkish children following toxoplasmosis and Behçet's disease.¹⁸ Although sufficient data is available, it is difficult to compare the frequency of idiopathic pars planitis among previously published series, since in some series, cases with pars planitis have been considered as idiopathic uveitis, while in others, it has been reported as a distinct entity.¹³

Pars planitis predominantly affects children and adolescents.^{13,5,7,10,13} Rosenberg et al reported that the occurrence of pars planitis was highest in children 6 to 10 years of age.¹⁰ Likewise Nikkhah et al reported that mean age at diagnosis was 7.8 years.⁷ Similar figures ranging from 9 to 10 years of age have been stated by most other authors.¹³⁻¹⁵ Arellanes-Garcia et al showed that 85% of patients were 14 years of age or younger at diagnosis, and that the mean age when symptoms began, was 6 years.¹⁵ However, Donaldson et al reported a higher mean age of 22.6 years in a 20-year population-based study on pars planitis.⁵

The gender distribution is controversial. Male predominance has been reported by Paroli et al (62%) and Romero et al (68.8%).^{13,14} Similarly, Nikkhah et al found marked male predominance with a male to female ratio of 5 to 1.⁷ However, in some other reports, female predominance has been noted.^{5,16} Gender distribution seems to be affected by the age of patients. In two recent studies comparing childhood-onset and adulthood-onset cases, boys comprised the majority of childhood cases, while women made up most adult cases.^{17,13}

Pars planitis usually affects both eyes; however, it may demonstrate asymmetrical involvement and the less affected eye can show only a few cells in the vitreous.^{3,14} In the majority of studies, over 75% of patients were reported to have bilateral disease. High bilaterality rates ranging from 84 to 92% have been reported in different studies.^{7,13,14,19}

Although some etiopathogenetic studies have suggested an autoimmune process with a genetic

predisposition, the etiology of pars planitis still remains unknown.^{14-16,20} Associations between pars planitis and HLA-DR2, -DR15, -B51 and -DRB1*0802 haplotypes have been described suggesting an immunogenetic predisposition.^{15,16,20,21} Patients who were HLA-DR15 positive were reported to have systemic findings of other HLA-DR15 related disorders such as multiple sclerosis (MS), optic neuritis and narcolepsy, suggesting a common genetic background.^{15,20,21} In Mexican Mestizos, more severe inflammation has been associated with HLA-B51 in female patients and with HLA-DRB1*0802 in male subjects.¹⁵

Smith et al reported race and ethnicity to be associated with predisposition to different patterns of uveitis, as well as pars planitis. They found that in their pediatric population, the prevalence of pars planitis was significantly lower in Hispanic children as compared to non-Hispanics (9.6% versus 19.2%).⁹

CLINICAL CHARACTERISTICS

The most common symptoms at presentation are floaters and blurred vision. Donaldson et al reported blurred vision in 74% and floaters in 61% of cases at the time of diagnosis.⁵ Prieto et al showed even higher rates of blurred vision (81.8%), while floaters were rarely reported (9%).²² Other less common symptoms included pain (6.5%), photophobia (6.5%) and red eye (4.3%).⁵ In severe cases, significant visual loss may occur due to aggregation of floaters in the vitreous or macular edema.²³ The disease may be asymptomatic and diagnosed incidentally during routine eye examination, especially in young children.^{13,14} Young children may even present with strabismus secondary to development of amblyopia or complications which cause leukocoria.^{13,13} Although pars planitis is known to be a benign form of uveitis in most cases, the clinical severity of the disease may vary widely. Since the anterior segment is often quiet and symptoms are minimal, the diagnosis of pars planitis is often delayed leading to complications and permanent visual loss in small children.

Mild to moderate anterior segment inflammation with small, round, white keratic precipitates (KPs) may occur in 28-50% of patients.^{13,5,14,20} Anterior chamber cells are the most commonly reported anterior segment findings. Posterior synechiae particularly involving the inferior iris may especially occur in childhood pars planitis.^{3,5} Peripheral corneal endotheliopathy has been reported, defined as peripheral corneal edema with small and mutton fat keratic precipitates linearly arranged on the border between edematous and normal cornea indicating an autoimmune origin of pars planitis [Figure 1].^{24,25} Anterior segment inflammation, band keratopathy, peripheral corneal endotheliopathy, and posterior synechiae are observed more often in children as compared to adults.³

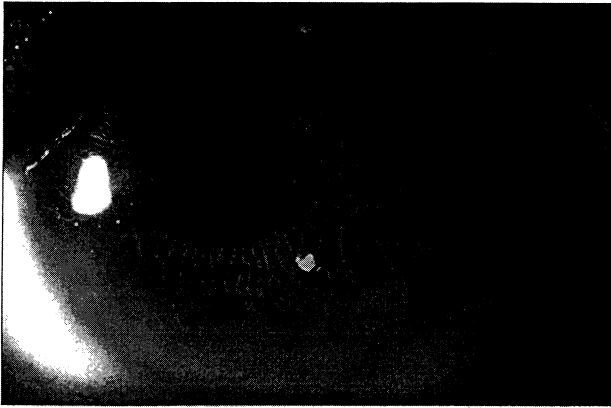


Figure 1. Slit lamp photograph shows posterior synechiae and peripheral corneal endotheliopathy in a child with pars planitis.




Figure 2. Slit lamp photograph shows dense vitreous condensation and opacities behind the lens in a child with pars planitis.

Diffuse vitreous cells, haze, snowballs and snowbanks are the typical findings in pars planitis [Figure 2].¹³ Vitreous snowballs are yellow-white inflammatory aggregates usually found in the mid-vitreous and inferior peripheral vitreous [Figure 3]. Snowbanks are exudates on pars plana, usually located inferiorly. Snowbanks have been observed in around 60-65% of cases.²⁰ Donaldson et al reported snowballs in 67.4% and snowbanks in 97.8% of eyes with pars planitis.⁵

Sheathing of peripheral retinal venules is another common clinical finding in patients with intermediate uveitis [Figure 4]. The frequency of retinal vasculitis is variable, ranging from 17% to 90% in previous studies.^{5,14-16,22} Optic disc edema is also common, found in around 70% of the cases when fluorescein angiography is performed.^{120,26}

OCULAR COMPLICATIONS

Pars planitis may lead to blindness due to complications and permanent damage to ocular structures, especially if the diagnosis is delayed.¹⁹ Owing to the chronic and asymptomatic course, delayed diagnosis and treatment is prevalent particularly among pediatric subjects. In a recent study, children with disease onset at 7 years of age or younger were reported to be more prone to development of complications such as cataract, glaucoma and vitreous hemorrhage, and had worse visual prognosis as compared to older children.²⁷

The most frequent complications of pars planitis include cataract, cystoid macular edema, vitreous opacities and optic disc edema. Band keratopathy, amblyopia, epiretinal membrane formation, vitreous condensation, neovascularizations, vitreous hemorrhage, retinal detachment and cyclitic membranes are also well known consequences of chronic pars planitis [Figures 5a, b and 6].^{5,7,10,14,19,22,23} Preverbal children may present with late-stage disease and severe visual impairment. Occasionally, dense vitreous

condensation may cause leukocoria which may be mistaken for cataracts particularly in young children.³¹

In the majority of studies, cataracts were the most frequent reported complication of pars planitis occurring at high rates ranging from 30.4% to 47.5%.^{5,7,14,15} In the study by Prieto et al, however, the most common complication of pars planitis was cystoid macular edema (47.7%), closely followed by vitreous opacities (38.6%), optic disc edema (38.6%) and vasculitis (36.4%).¹²² Similarly, Kump et al as well as Paroli et al reported the most frequent complication of intermediate uveitis to be cystoid macular edema and related macular changes in the pediatric population (39% and 25.7%, respectively).^{13,29} Cystoid macular edema has been reported to be the leading cause of visual morbidity in children with pars planitis [Figure 5a and b].^{12,26} It is related to disease chronicity, with a reported interval of 5.7 years between disease onset and the development of cystoid macular edema.⁵

Donaldson et al observed epiretinal membranes in 36.9% of subjects as the most common complication in their series, followed by cataract (30.4%) and cystoid macular edema (26%). Epiretinal membrane formation was found to be directly related to disease chronicity, and the mean interval between disease onset and epiretinal membrane formation was 7.9 years.¹⁵

Optic disc neovascularization due to severe intraocular inflammation, neovascularization elsewhere or in the snowbank and peripapillary subretinal neovascularization have also been reported in pars planitis.²⁰ Pars planitis is the leading cause of vitreous hemorrhage in children which is associated with neovascularization of the optic disc or the peripheral retina.^{3,29} In a series conducted by Lauer et al, vitreous hemorrhage was observed in 28% of children as compared to 6% of adults.²⁹ Although optic disc edema is a common sign, severe optic disc swelling




Figure 3. Fundus photograph shows inferiorly located snow ball opacities in a patient with pars planitis.

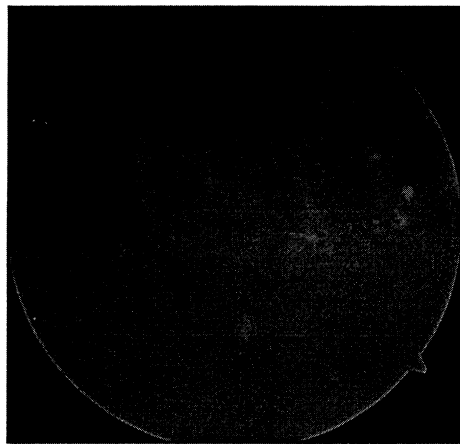


Figure 4. Fundus photograph shows inferiorly located snow ball opacities, vitreous veils and vascular sheathing in a patient with pars planitis.

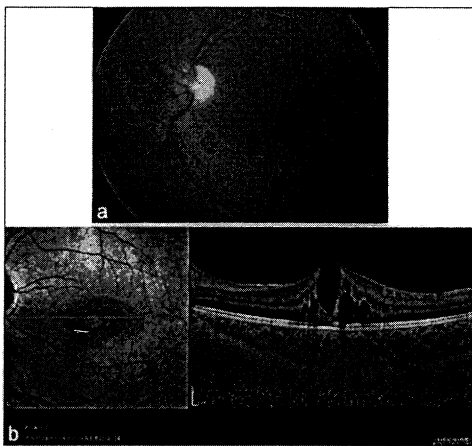


Figure 5. (a) Fundus photograph shows mild vitreous haze, epiretinal membrane nasal to the disc and cystoid macular edema in a child with pars planitis. (b) Optical coherence tomography shows the cystoid macular edema in the same patient.




Figure 6. Fundus photograph shows opacified posterior hyaloid in a child with pars planitis.

and optic atrophy due to optic disc edema are unusual complications.^[13,20]

Retinal detachment (tractional, rhegmatogenous or exudative) rarely occurs in pars planitis and has been reported in up to 10% of cases.^[5,13-15,30] Malinowski et al demonstrated that patients with lens opacity have a higher risk of developing retinal detachment.^[30] Inferior peripheral retinoschisis is another complication which occurs almost exclusively in children [Figure 7].^[13] Romero et al reported retinoschisis in 13.3% of cases.^[14] Jalil et al described peripheral retinal elevation in 11 eyes with pars planitis of which, 54.5%, 18.2% and 27.3% had tractional retinoschisis, tractional retinal detachment and flat retinal elevation of indeterminate type, respectively. They explained the pathogenesis of peripheral retinal elevation to be traction by gliosis over the ora serrata induced by previous snowbanking. Since traction is

not exerted by peripheral vitreous (which is already detached), but rather by glial fibrosis or snowbanking, these peripheral retinal elevations have a self-limited nature with long-term stability in most cases.^[31] Pollack et al, on the other hand, suggested a vascular etiology believing that chronic inflammation caused peripheral angiogenesis leading to either exudative retinal detachment or low-grade intraretinal edema, cyst formation and finally retinoschisis.^[32]

Although band keratopathy may occur at any age, it is mainly considered to be a hallmark of childhood pars planitis.^[33] Band keratopathy has been reported in up to 45% of affected eyes [Figure 8].^[20] Peripheral corneal endotheliopathy similar to the one seen in corneal allograft rejection has been found in 25% of patients.^[15] Glaucoma is a rare complication observed in approximately 6-8% of patients and requires filtering surgery in half of the cases.^[7,20] There are also few reports of macular hole and macular ectopia as uncommon complications.^[20]




Figure 7. Fundus photograph shows inferior retinoschisis in a child with pars planitis.

Young children with pars planitis are at high risk of amblyopia and delayed treatment may result in permanent visual loss. Amblyopia may occur due to band keratopathy, vitreous opacities and cataracts obscuring the visual axis, or persistent macular edema.^{133,34}

IMAGING IN PARS PLANITIS

Digital color fundus photography in uveitis allows documentation of baseline appearance of retinal lesions and helps to assess progression of the condition and response to treatment during follow up. Peripheral retinal pathologies such as snowbanking, retinoschisis, peripheral tractional membranes and macular complications such as macular edema, epiretinal membranes, atrophy and scars can be documented by colour fundus photography. However, visualization of the peripheral retina may be poor due to astigmatism induced by the angle of the fundus camera in relation to the crystalline lens, as well as the hazy vitreous in pars planitis.¹³⁵

Retinal fluorescein angiography (FA) is beneficial to show the activity of retinal vascular inflammation in pars planitis. FA is usually performed for two reasons in pars planitis: To assess the presence of cystoid macular edema and to examine retinal vasculature for signs of perivasculitis and retinal neovascularization.³⁶ Early hyperfluorescence with late leakage is usually present in the area of pars plana snowbanks. FA is also a valuable technique in documenting the response to treatment, especially in eyes with cystoid macular edema and peripheral vasculitis.¹³⁷ Indocyanine green (ICG) angiography has no clinical benefit in pars planitis and may only be used to rule out choroidal inflammation in equivocal cases.

Optical coherence tomography (OCT) is a very useful diagnostic technique for evaluation of retinal layers, and

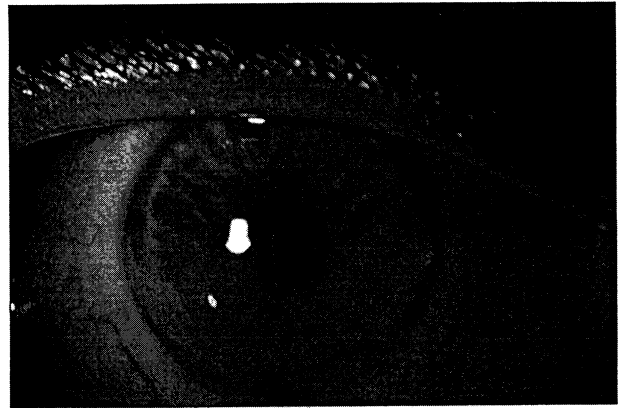


Figure 8. Slit lamp photograph shows band keratopathy and seclusio pupillae in a child with pars planitis.

retinal and macular pathologies related to intraocular inflammation. As described by Pakzad-Vaezi et al, OCT imaging in uveitis can provide both qualitative and quantitative information and may give information regarding the reversibility of lesions.¹³³ Chronic inflammation in pars planitis frequently causes cystoid macular edema. OCT is valuable in detecting macular edema and its sequelae such as cystoid changes, epiretinal membranes, macular hole and atrophy. Moreover, it is advantageous for monitoring the response to treatment. Visual potential and prognostic factors can also be determined by OCT. Pakzad-Vaezi et al described correlations between vision and foveal thickness, and reported poorer visual prognosis with IS/OS junction abnormalities demonstrated by OCT. Identification of prognostic factors may lead to more proper therapeutic decision making. For instance, macular edema with healthy IS/OS junction should aggressively be treated to preserve vision. On the contrary, chronic macular edema sequelae and abnormal IS/OS findings show poor prognosis and irreversible vision loss which may be followed using a more conservative approach.³³

Cataract, synechiae and vitreous inflammation may prevent visualization of the fundus in pars planitis. FA and OCT cannot provide adequate information about the retina in such cases. Ultrasonography and ultrasound biomicroscopy are valuable instruments promising additional information regarding the ciliary body, pars plana and retina in uveitis cases and poor visualization of the fundus.

Ultrasonography is a noninvasive and easy method for evaluation of the vitreous and retina in subjects with vitreous inflammation, hemorrhage or cataract. The conventional ultrasound device uses frequency in the range of 8-10 MHz for standard examination, while higher frequencies such as 20 and 50 MHz can provide fine resolution within the posterior and anterior segment. Doro et al showed that ultrasound examination with both the 50- and 20-MHz frequencies can detect the typical

snowbanks in intermediate uveitis and be useful in eyes with small pupil and dense vitritis. They concluded that the 50-MHz imaging was superior for visualization of angle structures and details of pars planitis; anterior vitreous involvement and cyclitic bands were more ideally shown with the 20-MHz probe, which could also evidence cystoid macular edema.³⁹

Ultrasound biomicroscopy is a valuable instrument which can be used for the diagnosis of problems affecting the ciliary body, pars plana and peripheral retina. It is similar to conventional B-scan ultrasonography except for the higher frequency (35-100 MHz) employed which provide high resolution images in the pars plana region. It is very helpful to detect snowbanks, cyclitic membranes, vitreous membranes and peripheral vitreoretinal tractions. It is also useful for monitoring the response to treatment.^[20,40,41]

DIAGNOSIS AND DIFFERENTIAL DIAGNOSIS

The diagnosis of idiopathic pars planitis is based on clinical findings. It may be underdiagnosed when inferior snowballs or snowbanks are missed, especially when ophthalmoscopy with scleral depression is not performed. There is no specific diagnostic laboratory test. However, systemic associations and mainly infectious causes of intermediate uveitis need to be ruled out. Systemic investigations include serological tests, chest x-ray, purified protein derivative skin test and brain magnetic resonance imaging. Because of the significant association of the condition with MS neuro-imaging should be performed in adult patients, in whom systemic associations are more common.

In children, pars planitis should be differentiated from chronic anterior uveitis which may be idiopathic or associated with juvenile idiopathic arthritis (JIA). Both entities have a chronic and asymptomatic course leading to similar complications. The presence of prominent anterior segment inflammation and related complications such as band keratopathy, posterior synechiae, and cataract in pediatric pars planitis may lead to a misdiagnosis of chronic anterior uveitis, especially when posterior segment findings cannot be adequately visualized. Inflammation affecting primarily the anterior segment of the eye and the presence of chronic arthritis are the most important clues in diagnosing JIA associated uveitis.^[42]

Sarcoidosis is another entity that should be considered in the differential diagnosis of childhood pars planitis. It usually presents as a chronic granulomatous anterior uveitis with mutton fat KPs, broad based posterior synechiae, and iris nodules. Young children with sarcoidosis do not typically have pulmonary involvement, but may present with polyarthritis, skin

nodules and uveitis. Serum angiotensin converting enzyme (ACE) levels should be compared to age-matched controls because ACE levels are commonly higher in children as compared to adults.^[43] Although the definite diagnosis needs a biopsy specimen, ocular sarcoidosis can be clinically diagnosed based on clinical findings and laboratory abnormalities in older children and the presence of skin lesions and arthritis in younger children.^[3]

Familial juvenile systemic granulomatosis known as Blau syndrome has clinical findings similar to childhood sarcoidosis and is characterized by granulomatous polyarthritis, skin rash and uveitis.^[44] Family history and acute granulomatous nature of uveitis affecting the anterior segment of the eye are helpful in making the differentiation. Multiple sclerosis is very rare in children; however, children with pars planitis may later develop MS during adolescence or in adulthood.^[29] In unilateral cases, ocular toxocariasis should also be considered. Peripheral toxocara granuloma may sometimes be difficult to distinguish from snowbanking in idiopathic pars planitis. Serology and ultrasound biomicroscopy are of value for the diagnosis of ocular toxocariasis. Masquerades are other differential diagnosis. In children, retinoblastoma may present as cellular reaction or white deposits in the anterior chamber and vitreous infiltrates. Diagnostic fine needle aspiration biopsies should be performed in such unusual cases.^[45]

In adults, the presence of granulomatous anterior uveitis along with clinical findings of pars planitis suggests sarcoidosis, tuberculosis and MS. In a series of 62 patients with pars planitis, Zierhut and Foster found six cases of biopsy proven sarcoidosis and an additional nine patients suspected to have sarcoidosis because of elevated ACE levels. They also showed that patients may develop sarcoidosis after the onset of pars planitis.^[46] Pulmonary manifestations such as hilar lymphadenopathy, serum ACE and lysozyme levels, gallium scan, chest computed tomography, biopsy from conjunctival nodules or skin granuloma, bronchoalveolar lavage and transbronchial lung biopsy are helpful in diagnosing sarcoidosis.^[47,43] *Mycobacterium tuberculosis* may also induce a clinical picture similar to pars planitis. Accurate history, chest imaging, tuberculin skin test and interferon gamma release assays should be performed to rule out tuberculosis especially in patients living in endemic areas.^[48]

A strong association between pars planitis and MS has been shown [Figure 9].^[22,29,16] In the presence of symptoms or clinical signs suggestive of MS such as prominent retinal periphlebitis and optic neuritis, a magnetic resonance imaging (MRI) of brain and cerebrospinal fluid analysis should be performed.^[16] Behçet uveitis may be misdiagnosed as pars planitis in patients who present with diffuse bilateral vitreous cells and inferior pearl-like

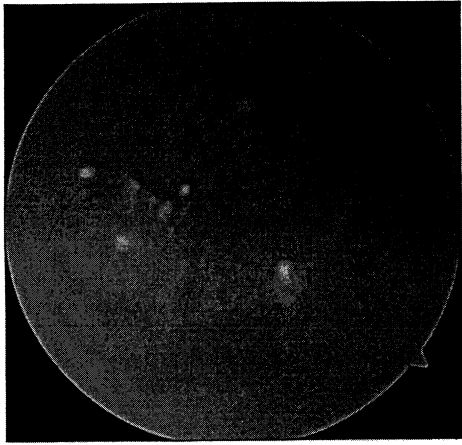


Figure 9. Fundus photograph shows peripheral vascular sheathing and snow ball opacities similar to pars planitis in a patient with multiple sclerosis.

precipitates. Characteristics of Behçet uveitis such as the history of recurrent ocular inflammatory attacks, acute onset and spontaneous resolution of inflammation, appearance of inferior peripheral precipitates during resolution of vitreous haze, and absence of snowballs, snowbanks or persistent vitreous condensates are helpful to differentiate it from pars planitis. Pearl-like precipitates seen in Behçet uveitis are small, uniform and immobile, and are located on the surface of the retina, whereas snowball opacities are mobile, round, white collections in the vitreous.^[49]

Fuchs' uveitis syndrome (FUS) should also be included in the differential diagnosis of pars planitis because of prominent vitreous infiltration and condensations. However, FUS has characteristic features including unilaterality, the presence of diffusely distributed small, round or stellate KPs, iris atrophy with or without heterochromia, and the absence of macular edema.^[50] Lyme disease, a spirochaetal infection caused by *Borrelia burgdorferi* may present with pars planitis and should also be differentiated in this subset of patients specifically if a history of exposure to ticks, rash and chronic arthritis are present. Lyme indirect immunofluorescence assay and Lyme enzyme-linked immunosorbent assay are helpful in making the diagnosis of Lyme disease.^[36,47,48] Although rare, serologic tests for syphilis and cat-scratch disease should also be considered in the clinical picture of intermediate uveitis. Inflammatory bowel disease is another entity which may present with clinical findings of pars planitis. Patients with history of chronic or bloody diarrhea should be referred to a gastroenterologist.^[36]

In the elderly, primary intraocular lymphoma is the most important entity to be differentiated from pars planitis. It may present with diffuse vitreous infiltration, which may mimic intermediate uveitis. Along with severe vitreous inflammation, chorioretinal lesions and poor or partial response to therapy are highly suggestive

of primary intraocular lymphoma. Although it is typically seen in the elderly population, it may also develop in young individuals.^[48] Brain MRI, cerebrospinal fluid analysis and careful neurologic history may provide useful information in diagnosing primary central nervous system lymphoma which may be associated with primary intraocular lymphoma. However, cytological evaluation of vitreous samples, identification of cell surface markers by immunohistochemistry, cytokine analysis, retinal biopsy and gene rearrangement are required for a definitive diagnosis of intraocular lymphoma. While IL-10 is preferentially expressed by B-cell malignancies, IL-6 is produced by inflammatory cells and an elevated IL-10/IL-6 ratio in aqueous humor or vitreous is highly suggestive of intraocular lymphoma.^[51]

TREATMENT

Exclusion of infectious and non-infectious causes which may present with intermediate uveitis is of utmost importance before starting treatment. The decision of treatment in a patient with pars planitis is still a controversial issue. There is no consensus especially for cases with minimal inflammation and relatively good visual acuity. According to guidelines suggested by Forrester et al, visual acuity of 20/40 was considered as the threshold for treatment decision in pars planitis and only patients with visual acuity worse than this level were treated, while other cases were only observed.^[52] This approach cannot be approved with our current knowledge about the disease. Pars planitis is a severe disease which may cause several ocular complications and thus needs an aggressive treatment. As Foster et al pointed out, treating inflammation early and aggressively, rather than using a visual acuity threshold, is more effective both in short and long term. They reported that a significant number of patients (20%) who were allowed to wait until visual acuity reached <20/40 for treatment, were never able to recover normal vision even when treated.^[48] Currently, the presence of macular edema, vitreous haze leading to a decrease in visual acuity, complications such as band keratopathy, cataract, or retinoschisis in at least one eye, vasculitis and a severe infiltration of the pars plana are indications for treatment irrespective of the level of visual acuity.

A stepladder approach is the most widely used method in treating patients with pars planitis. The order of steps, however, may vary between practitioners. A four-step approach was firstly described by Kaplan in 1984 and consisted of: 1. Periocular corticosteroid (CS) injections followed by oral prednisone if considered ineffective, 2. cryotherapy or laser photocoagulation, 3. pars plana vitrectomy and 4. immunosuppressive treatment.^[53] This approach is no longer recommended as ophthalmologists have more experience with the use of immunosuppressive agents and new biological

treatments.⁴⁷ Foster modified Kaplan's algorithm to a five-step approach and recommended the use of systemic non-steroidal anti-inflammatory drugs (NSAIDs) as a second step in patients not responding to three periocular CS injections. Systemic CS, used not more than three months, made the third step in this modified stepladder approach and was followed by cryotherapy or laser photocoagulation and pars plana vitrectomy (PPV) or immunosuppressive treatment as fourth and fifth steps, respectively.⁴³

In our current practice, the first treatment step is the use of CS which is still the mainstay of treatment. Topical CSs are used only if there is anterior segment inflammation. They are ineffective for treatment of intermediate uveitis especially in phakic cases. Systemic or periocular CSs, however, are required in most patients. Periocular CS injections are beneficial particularly in patients with unilateral or asymmetrical involvement and in the presence of macular edema. Injection of 40 mg triamcinolone acetonide retroseptally through the lower lid or superotemporally into the subtenon space is the preferred method of employing periocular CS. Two or three injections over a 6-8 week period are suggested before considering the modality as ineffective.^{36,43} In a series by Helm et al, an improvement of at least two Snellen lines of visual acuity has been reported following posterior subtenon injection of triamcinolone acetonide.¹⁵⁴ The most common complications of periocular CS are increased intraocular pressure, cataract and aponeurotic ptosis.¹²³ Intravitreal CS injections have also been found effective in treating intermediate uveitis and associated macular edema.^{155,56} High rates of complications including cataract, increased intraocular pressure, glaucoma, vitreous hemorrhage, retinal detachment and endophthalmitis should always be considered before performing an intraocular CS injection.¹⁵⁷ We agree that this technique should remain an emergency procedure when essential structures such as the macula have to be saved immediately and allow time to organize the long term management.¹⁴⁷ Recently, an intravitreal dexamethasone implant (Ozurdex®; Allergan, Irvine, CA, USA) has been approved for treatment of intermediate and posterior uveitis. It has been reported to improve vision persisting for six months in eyes with noninfectious intermediate or posterior uveitis with a favorable safety profile.¹⁵⁸ A recent study by Taylor et al reported the intravitreal dexamethasone implant as an effective therapy for controlling childhood intraocular inflammation including intermediate uveitis.¹⁵⁹ However, there is not enough data yet regarding how often a reinjection will be required and the frequency of complications following repeated injections. It is clear that the treating physician has to weigh the risks and benefits of local versus systemic treatment.

Patients with bilateral involvement, severe ocular inflammation or unilateral disease unresponsive to

periocular CS treatment should be treated systemically. A dose of 1-1.5 mg/kg/day of prednisone tapered according to clinical response is preferred by most uveitis specialists. Intravenous pulse methylprednisolone therapy (1 gr/day for adults, 30 mg/kg for children) may be administered when more rapid and potent action is needed.

Steroid-sparing immunosuppressive therapy should be considered as a second step in patients who require long-term treatment. Methotrexate (especially in pediatric patients), mycophenolate mofetil, azathioprine and cyclosporine may be used alone or in combination. The choice of immunosuppressive agent may change according to ophthalmologist's preference and experience and also to patient's clinical findings and age. Methotrexate is the most widely used first-line immunosuppressive agent in children with chronic non-infectious uveitis because of its long-term safety record and well tolerance. Cyclosporine has also been reported effective for the treatment of pars planitis by Nussenblatt and Palestine.⁶⁰ Biswas and Sudharshan preferred the use of azathioprine owing to its cost effectiveness and low side effect profile.⁴⁷ It is of importance to remember that these agents need 4-8 weeks to become effective and CS should be given concomitantly until the immunosuppressive agent is expected to take action. Due to serious potential side effects, alkylating agents such as cyclophosphamide and chlorambucil should be avoided especially in children. This stepladder approach may be modified according to patient's findings and needs. For instance, in patients who present with serious ocular complications, immunosuppressive agents and CS combination may be started as the first step.

Anti-tumor necrosis factor- α (Anti-TNF- α) agents may be used successfully as the third step in patients not responding to conventional immunosuppressive agents. Although there is no study directly addressing the use of these agents in pars planitis or other non-infectious intermediate uveitis, clinical experience suggests promising efficacy from the use of these agents, especially in refractory ocular inflammation. Both infliximab and adalimumab have been proved to be effective in pediatric uveitis including pars planitis.⁶¹⁻⁶⁴ Studies comparing adalimumab and infliximab for the treatment of pediatric chronic non-infectious uveitis showed a similar effect in terms of remission of inflammation. However, in preventing the uveitis attacks and maintaining the remission, adalimumab was found to be more efficient than infliximab. It has been recently reported that the use of adalimumab as the first anti-TNF- α agent was more effective as compared to its use in cases of infliximab failure.^{65,66} As pars planitis is associated with an increased risk for MS development and anti-TNF- α agents may potentiate demyelinating disease, extreme caution is needed before starting such therapy in

patients with pars planitis.¹⁴³ Interferon (IFN) alpha had previously been shown to improve macular edema due to non-infectious uveitis in 24 patients, of which 18 subjects had intermediate uveitis.¹⁶⁷ A very recent study comparing the efficacy of 20 mg/week methotrexate subcutaneously with 44 µg of interferon-beta three times a week for treatment of macular edema associated with intermediate uveitis showed that interferon-beta was superior.¹⁶³ Additionally, vitreous haze improved in the group using interferon, whereas it remained unchanged in the group using methotrexate. The only limitation of this study was the small sample size.¹⁶³ Although there is no direct comparison of IFN beta versus IFN alpha in the treatment of uveitis, Mackensen et al suggested that these agents were similarly effective based on published data and experience from their clinical practice.¹⁶³

Pars plana vitrectomy (PPV) comprises the fourth step of therapy particularly in patients developing complications such as vitreous condensation, vitreous hemorrhage, retinal detachment, and epiretinal membranes causing retinal traction. PPV has also been shown to be effective in patients with active inflammation and cystoid macular edema refractory to medical treatment.¹⁶⁹⁻⁷² Advantages of PPV have been reported to be mechanical clearance of inflammatory mediators and debris, anatomical correction of retinal pathology such as vitreoretinal traction, opportunity to obtain vitreous samples for adjunctive diagnostic purposes and reduction of postoperative anti-inflammatory medication.^{123,70,72} Trittibach et al reported promising results from PPV on the course of pediatric and juvenile chronic uveitis, showing a significant improvement in visual acuity and reduction in postoperative cystoid macular edema (CME).¹⁷¹ In a small series (16 patients) comparing PPV with immunomodulatory therapy in active intermediate uveitis, patients treated with PPV had a higher rate of uveitis resolution (82% vs 43%).¹⁷⁰ Even though there was no statistically significant difference regarding visual outcomes during the 18-month follow-up period, the authors suggested PPV as a method providing better control of inflammation and resulting in immunosuppressive-sparing effect in the majority of patients.¹⁷⁰ Schonfeld et al, on the other hand, reported a visual acuity of 20/200 in 75% of their subjects with intermediate uveitis who underwent PPV. This unfavorable result has been attributed to the pre-existing macular pathology.¹⁷³

The rationale for performing cryotherapy and laser photocoagulation before the immunosuppressive treatment both in Kaplan's and Foster's stepladder approaches, was to induce regression of vitreous base neovascularization and consequently stabilize the inflammation.^{53,43} Although favorable results with cryotherapy have been previously reported,⁷⁴⁻⁷⁶ it is believed that cryotherapy aggravates blood-ocular barrier disruption and possibly accelerates the rate of retinal detachment in a predisposed

eye by inducing vitreous contraction.¹⁴³ Compared to cryotherapy, laser photocoagulation is an easier and safer method with fewer ocular complications. It has been shown to be effective for treatment of peripheral retinal neovascularization.^{177,78} Pulido and associates hypothesized that laser photocoagulation helps diminish inflammation in pars planitis by decreasing the release of angiogenic factors.¹⁷⁹ In our opinion, laser photocoagulation should not be considered as a treatment step alone; however, it may be employed as an adjunctive treatment modality especially in cases associated with peripheral neovascularization, retinal traction or retinoschisis.

Cataract surgery using phacoemulsification and intraocular lens implantation has been reported to be safe in cases with pars planitis.^{180,31} After preoperative control of inflammation for three months, visual acuity of $\geq 20/40$ could be achieved in 88% of patients following cataract surgery.³¹ Ganesh and co-workers evaluated their results on phacoemulsification and intraocular lens implantation in patients with pars planitis and reported that 91% of subjects had better visual acuity as compared to preoperative values.¹⁸⁰ As in all uveitis cases, adequate preoperative control of inflammation, a meticulous surgical technique, a foldable hydrophobic acrylic intraocular lens implanted in the capsular bag and good postoperative inflammation control are crucial for successful cataract surgery in pars planitis patients.

COURSE AND PROGNOSIS OF PARS PLANITIS

The natural course of pars planitis is varied. Smith et al reported that 10% of patients had a self-limited course, whereas 59% had a prolonged course with exacerbations and 31% had a chronic smoldering course with few episodes of exacerbations.¹⁸² Furthermore, due to this chronic course, up to 70% of patients develop complications leading to visual loss.⁷⁰ Thus the disease warrants a treatment strategy based on regular evaluation of patients. Because of the chronic, insidious nature of the disease and the fact that the anterior segment is often quiet, children with pars planitis may present with permanent visual loss. The prognosis for pars planitis in children depends on the severity of vitreous inflammation. Eyes with more severe inflammation are more prone to develop macular edema while those with vitreous strands may sustain retinal traction and detachment.³³ Adequate control of inflammation and prompt detection of associated complications are essential in improving the overall prognosis of the patient.^{48,70}

An important factor affecting visual prognosis seems to be patient age. Children presenting with pars planitis have worse visual acuity level at initial diagnosis and during follow-up as compared to adults.¹² It has been

shown that children with disease onset at 7 years of age or younger were more prone to development of complications and had worse visual prognosis as compared to older children.¹²⁷ Accordingly, Paroli et al suggested age of onset of 10 years or less as a risk factor for visual loss. Other risk factors were reported to be male gender, duration of uveitis more than 3 years prior to presentation, anterior chamber cells, marked vitreous haze with snowballs and snowbanks and macular edema. The most common causes of severe visual loss were macular edema in 64%, cataract in 21% and retinal detachment in 14% of cases.¹³ In the other study, better baseline visual acuity, age older than 5 years at onset, absence of corneal endotheliopathy and female gender were found to be associated with best corrected visual acuity (BCVA) of $\geq 20/40$.¹⁷¹

Another prognostic consideration in pars planitis is its association with MS. Malinowski et al demonstrated a strong association between pars planitis and MS. In their series, MS developed in 8 (14.8%) out of 54 patients with pars planitis.¹³⁰ They stated that retinal periphlebitis at the time of diagnosis increased the risk of MS and/or optic neuritis. Raja et al reported their long-term follow-up findings in pars planitis and showed that 16.2% of subjects developed MS.¹⁶ Moreover, both studies implicated the importance of the HLA-DR locus in the pathogenesis of both entities and showed that HLA-DR2 and HLA-DR15 were closely associated with both pars planitis and MS.^{16,30}

Because of the chronic and insidious nature of pars planitis leading to various vision-threatening complications, it should be considered as a potentially blinding disease. As compared to adults, children have a more severe course and poorer visual prognosis. Delayed diagnosis and treatment may result in severe visual loss and amblyopia especially in children. Early and aggressive treatment is effective in terms of preserving visual function, rather than waiting until visual acuity is decreased. Current four-step therapy consists of corticosteroids, immunosuppressives, anti-TNF- α agents and finally pars plana vitrectomy and/or laser photocoagulation for the management of complications. Patients with pars planitis should also be screened for the association of multiple sclerosis in the long-term.

Financial Support and Sponsorship

Nil.

Conflicts of Interest

There are no conflicts of interest.

REFERENCES

- Jabs DA, Nussenblatt RB, Rosenbaum JT; Standardization of Uveitis Nomenclature (SUN) Working Group. Standardization of uveitis nomenclature for reporting clinical data. Results of the First International Workshop. *Am J Ophthalmol* 2005;140:509-516.
- Zierhut M, Michels H, Stübiger N, Besch D, Deuter C, Heiligenhaus A. Uveitis in children. *Int Ophthalmol Clin* 2005;45:135-156.
- Tugal-Tutkun I. Pediatric uveitis. *J Ophthalmic Vis Res* 2011;6:259-269.
- Gritz DC, Wong IG. Incidence and prevalence of uveitis in Northern California; the Northern California Epidemiology of Uveitis Study. *Ophthalmology* 2004;111:491-500.
- Donaldson MJ, Pulido JS, Herman DC, Diehl N, Hodge D. Pars planitis: A 20-year study of incidence, clinical features, and outcomes. *Am J Ophthalmol* 2007;144:812-817.
- Vadot E. Epidemiology of intermediate uveitis: A prospective study in Savoy. *Dev Ophthalmol* 1992;23:33-34.
- Nikkhah H, Ramezani A, Ahmadi H, Soheilian M, Azarmina M, Dehghan MH, et al. Childhood pars planitis; clinical features and outcomes. *J Ophthalmic Vis Res* 2011;6:249-254.
- Soylu M, Ozdemir G, Anli A. Pediatric uveitis in Southern Turkey. *Ocul Immunol Inflamm* 1997;5:197-202.
- Smith JA, Mackensen F, Sen HN, Leigh JF, Watkins AS, Pyatetsky D, et al. Epidemiology and course of disease in childhood uveitis. *Ophthalmology* 2009;116:1544-1551, 1551.e1.
- Rosenberg KD, Feuer WJ, Davis JL. Ocular complications of pediatric uveitis. *Ophthalmology* 2004;111:2299-2306.
- Ozdam PC, Sen E, Yazici A, Ozturk F. Patterns of childhood-onset uveitis in a referral center in Turkey. *J Ophthalmic Inflamm Infect* 2012;2:13-19.
- Guest S, Funkhouser E, Lightman S. Pars planitis: A comparison of childhood onset and adult onset disease. *Clin Experiment Ophthalmol* 2001;29:81-84.
- Paroli MP, Spinucci G, Monte R, Pesci FR, Abicca I, Pivetti Pezzi P. Intermediate uveitis in a pediatric Italian population. *Ocul Immunol Inflamm* 2011;19:321-326.
- Romero R, Peralta J, Sendagorta E, Abelairas J. Pars planitis in children: Epidemiologic, clinical, and therapeutic characteristics. *J Pediatr Ophthalmol Strabismus* 2007;44:288-293.
- Arellanes-García L, Navarro-López L, Recillas-Gispert C. Pars planitis in the Mexican Mestizo population: Ocular findings, treatment, and visual outcome. *Ocul Immunol Inflamm* 2003;11:53-60.
- Raja SC, Jabs DA, Dunn JP, Fekrat S, Machan CH, Marsh MJ, et al. Pars planitis: Clinical features and class II HLA associations. *Ophthalmology* 1999;106:594-599.
- Paroli MP, Abicca I, Sapia A, Bruschi S, Pivetti Pezzi P. Intermediate uveitis: Comparison between childhood-onset and adult-onset disease. *Eur J Ophthalmol* 2014;24:94-100.
- Heinz C, Schoonbrood S, Heiligenhaus A. Intermediate uveitis in children and young adults: Differences in clinical course, associations and visual outcome. *Br J Ophthalmol* 2014;98:1107-1111.
- Kadayifçılar S, Eldem B, Tümer B. Uveitis in childhood. *J Pediatr Ophthalmol Strabismus* 2003;40:335-340.
- Arellanes-García L, Navarro-López P, Concha-Del Río LE, Unzueta-Medina JA. Idiopathic intermediate uveitis in childhood. *Int Ophthalmol Clin* 2008;48:61-74.
- Tang WM, Pulido JS, Eckels DD, Han DP, Mieler WF, Pierce K. The association of HLA-DR15 and intermediate uveitis. *Am J Ophthalmol* 1997;123:70-75.
- Prieto JF, Dios E, Gutierrez JM, Mayo A, Calonge M, Herreras JM. Pars planitis: Epidemiology, treatment, and association with multiple sclerosis. *Ocul Immunol Inflamm* 2001;9:93-102.
- Babu BM, Rathinam SR. Intermediate uveitis. *Indian J Ophthalmol* 2010;58:21-27.
- García LA, Ortiz-Ponce G, Recillas-Gispert C. Peripheral corneal

- endotheliopathy and pars planitis. *Ocul Immunol Inflamm* 1996;4:135-138.
25. Khodadoust AA, Karnama Y, Stoessel KM, Puklin JE. Pars planitis and autoimmune endotheliopathy. *Am J Ophthalmol* 1986;102:633-639.
 26. de Boer J, Berendschot TT, van der Does P, Rothova A. Long-term follow-up of intermediate uveitis in children. *Am J Ophthalmol* 2006;141:616-621.
 27. Kalinina Ayuso V, ten Cate HA, van den Does P, Rothova A, de Boer JH. Young age as a risk factor for complicated course and visual outcome in intermediate uveitis in children. *Br J Ophthalmol* 2011;95:646-651.
 28. Kump LI, Cervantes-Castañeda RA, Androudi SN, Foster CS. Analysis of pediatric uveitis cases at a tertiary referral center. *Ophthalmology* 2005;112:1287-1292.
 29. Lauer AK, Smith JR, Robertson JE, Rosenbaum JT. Vitreous hemorrhage is a common complication of pediatric pars planitis. *Ophthalmology* 2002;109:95-98.
 30. Malinowski SM, Pulido JS, Folk JC. Long-term visual outcome and complications associated with pars planitis. *Ophthalmology* 1993;100:818-824.
 31. Jalil A, Dhawahir-Scala FE, Jones NP. Nonprogressive tractional inferior retinal elevation in intermediate uveitis. *Ocul Immunol Inflamm* 2010;18:60-63.
 32. Pollack AL, McDonald HR, Johnson RN, Ai E, Irvine AR, Lahey JM, et al. Peripheral retinoschisis and exudative retinal detachment in pars planitis. *Retina* 2002;22:719-724.
 33. Holland GN, Stiehm ER. Special considerations in the evaluation and management of uveitis in children. *Am J Ophthalmol* 2003;135:867-878.
 34. Hamade IH, Al Shamsi HN, Al Dhibi H, Chacra CB, Abu El-Asrar AM, Tabbara KF. Uveitis survey in children. *Br J Ophthalmol* 2009;93:569-572.
 35. Gupta A, Gupta V. Fundus photography. In: Gupta A, Gupta V, Herbort CP, Khairallah M, editors. *Uveitis: Text and Imaging*. New Delhi, India: Jaypee Brothers; 2009. p. 50-60.
 36. Whitcup SM. Intermediate uveitis. In: Nussenblatt RB, Whitcup SM, editors. *Uveitis. Fundamentals and Clinical Practice*. China: Elsevier; 2010. p. 269-277.
 37. Josephberg RG, Kanter ED, Jaffee RM. A fluorescein angiographic study of patients with pars planitis and peripheral exudation (snowbanking) before and after cryopexy. *Ophthalmology* 1994;101:1262-1266.
 38. Pakzad-Vaezi K, Or C, Yeh S, Forooghian F. Optical coherence tomography in the diagnosis and management of uveitis. *Can J Ophthalmol* 2014;49:18-29.
 39. Doro D, Manfrè A, Deligianni V, Secchi AG. Combined 50- and 20-MHz frequency ultrasound imaging in intermediate uveitis. *Am J Ophthalmol* 2006;141:953-955.
 40. Greiner KH, Kilmartin DJ, Forrester JV, Atta HR. Grading of pars planitis by ultrasound biomicroscopy – echographic and clinical study. *Eur J Ultrasound* 2002;15:139-144.
 41. Ahn JK, Jeong IY. Ultrasound biomicroscopy in anterior uveitis. *Ophthalmology* 2008;115:1851, 1851.e1-3.
 42. Ozdal P, Tugal-Tutkun I. Inflammatory eye disease in children with chronic arthritis. *Ann Paediatr Rheumatol* 2013;2:62-77.
 43. Shetty AK, Gedalia A. Childhood sarcoidosis: A rare but fascinating disorder. *Pediatr Rheumatol Online J* 2008;6:16.
 44. Manouvrier-Hanu S, Puech B, Piette F, Boute-Benejean O, Desbonnet A, Duquesnoy B, et al. Blau syndrome of granulomatous arthritis, iritis, and skin rash: A new family and review of the literature. *Am J Med Genet* 1998;76:217-221.
 45. Gupta A, Gupta V. Paediatric uveitis. In: Gupta A, Gupta V, Herbort CP, Khairallah M, editors. *Uveitis: Text and Imaging*. New Delhi, India: Jaypee Brothers; 2009. p. 715-727.
 46. Zierhut M, Foster CS. Multiple sclerosis, sarcoidosis and other diseases in patients with pars planitis. *Dev Ophthalmol* 1992;23:41-47.
 47. Biswas J, Sudharshan S. Intermediate uveitis. In: Gupta A, Gupta V, Herbort CP, Khairallah M, editors. *Uveitis: Text and Imaging*. New Delhi, India: Jaypee Brothers; 2009. p. 348-362.
 48. Kump L, Vitale AT, Foster CS. Pediatric uveitis. In: Foster CS, Vitale AT, editors. *Diagnosis and Treatment of Uveitis*. New Delhi, India: Highlights Medical Publishers; 2013. p. 1223-1225.
 49. Tugal-Tutkun I, Gupta V, Cunningham ET. Differential diagnosis of behçet uveitis. *Ocul Immunol Inflamm* 2013;21:337-350.
 50. Tugal-Tutkun I, Güney-Tefekli E, Kamaci-Duman F, Corum I. A cross-sectional and longitudinal study of Fuchs uveitis syndrome in Turkish patients. *Am J Ophthalmol* 2009;148:510-515.e1.
 51. Davis JL. Diagnosis of intraocular lymphoma. *Ocul Immunol Inflamm* 2004;12:7-16.
 52. Forrester JV, Okada AA, Ben Ezra D, Ohno S, editors. *Pars planitis. In: Posterior Segment Intraocular Inflammation: Guidelines*. The Hague, Netherlands: Kugler Publications; 1998. p. 93-97.
 53. Kaplan HJ. Intermediate uveitis (pars planitis, chronic cyclitis) – A four step approach to treatment. In: Saari KM, editor. *Uveitis Update*. Amsterdam: Experta Medica; 1984. p. 169-172.
 54. Helm CJ, Holland GN. The effects of posterior subtenon injection of triamcinolone acetonide in patients with intermediate uveitis. *Am J Ophthalmol* 1995;120:55-64.
 55. Young S, Larkin G, Branley M, Lightman S. Safety and efficacy of intravitreal triamcinolone for cystoid macular oedema in uveitis. *Clin Experiment Ophthalmol* 2001;29:2-6.
 56. Hogewind BF, Zijlstra C, Klevering BJ, Hoyng CB. Intravitreal triamcinolone for the treatment of refractory macular edema in idiopathic intermediate or posterior uveitis. *Eur J Ophthalmol* 2008;18:429-434.
 57. van Kooij B, Rothova A, de Vries P. The pros and cons of intravitreal triamcinolone injections for uveitis and inflammatory cystoid macular edema. *Ocul Immunol Inflamm* 2006;14:73-85.
 58. Lowder C, Belfort R Jr., Lightman S, Foster CS, Robinson MR, Schiffman RM, et al. Dexamethasone intravitreal implant for noninfectious intermediate or posterior uveitis. *Arch Ophthalmol* 2011;129:545-553.
 59. Taylor SR, Tomkins-Netzer O, Joshi L, Morarji J, McLoone E, Lightman S. Dexamethasone implant in pediatric uveitis. *Ophthalmology* 2012;119:2412-2412.e2.
 60. Nussenblatt RB, Palestine AG. Cyclosporin (Sandimmun) therapy: Experience in the treatment of pars planitis and present therapeutic guidelines. *Dev Ophthalmol* 1992;23:177-184.
 61. Tugal-Tutkun I, Ayranci O, Kasapcopur O, Kir N. Retrospective analysis of children with uveitis treated with infliximab. *J AAPOS* 2008;12:611-613.
 62. Ardoin SP, Kredich D, Rabinovich E, Schanberg LE, Jaffe GJ. Infliximab to treat chronic noninfectious uveitis in children: Retrospective case series with long-term follow-up. *Am J Ophthalmol* 2007;144:844-849.
 63. Biester S, Deuter C, Michels H, Haefner R, Kuemmerle-Deschner J, Doycheva D, et al. Adalimumab in the therapy of uveitis in childhood. *Br J Ophthalmol* 2007;91:319-324.
 64. Gallagher M, Quinones K, Cervantes-Castañeda RA, Yilmaz T, Foster CS. Biological response modifier therapy for refractory childhood uveitis. *Br J Ophthalmol* 2007;91:1341-1344.
 65. Simonini G, Taddio A, Cattalini M, Caputo R, De Libero C, Naviglio S, et al. Prevention of flare recurrences in childhood-refractory chronic uveitis: An open-label comparative study of adalimumab versus infliximab. *Arthritis Care Res (Hoboken)* 2011;63:612-618.
 66. Simonini G, Taddio A, Cattalini M, Caputo R, de Libero C, Parentin F, et al. Superior efficacy of Adalimumab in treating

- childhood refractory chronic uveitis when used as first biologic modifier drug: Adalimumab as starting anti-TNF- α therapy in childhood chronic uveitis. *Pediatr Rheumatol Online J* 2013;11:16.
67. Deuter CM, Kötter I, Günaydin I, Stübiger N, Doycheva DG, Zierhut M. Efficacy and tolerability of interferon alpha treatment in patients with chronic cystoid macular oedema due to non-infectious uveitis. *Br J Ophthalmol* 2009;93:906-913.
 68. Mackensen F, Jakob E, Springer C, Dobner BC, Wiehler U, Weimer P, et al. Interferon versus methotrexate in intermediate uveitis with macular edema: Results of a randomized controlled clinical trial. *Am J Ophthalmol* 2013;156:478-486.e1.
 69. Heiligenhaus A, Bornfeld N, Foerster MH, Wessing A. Long-term results of pars plana vitrectomy in the management of complicated uveitis. *Br J Ophthalmol* 1994;78:549-554.
 70. Quinones K, Choi JY, Yilmaz T, Kafkala C, Letko E, Foster CS. Pars plana vitrectomy versus immunomodulatory therapy for intermediate uveitis: A prospective, randomized pilot study. *Ocul Immunol Inflamm* 2010;18:411-417.
 71. Trittbach P, Koerner F, Sarra GM, Garweg JG. Vitrectomy for juvenile uveitis: Prognostic factors for the long-term functional outcome. *Eye (Lond)* 2006;20:184-190.
 72. Stavrou P, Baltatzis S, Letko E, Samson CM, Christen W, Foster CS. Pars plana vitrectomy in patients with intermediate uveitis. *Ocul Immunol Inflamm* 2001;9:141-151.
 73. Schönfeld CL, Weisschädcl S, Heidenkummer HP, Kampik A. Vitreoretinal surgery in intermediate uveitis. *Ger J Ophthalmol* 1995;4:37-42.
 74. Aaberg TM, Cesarz TJ, Flickinger RR Jr. Treatment of pars planitis. I. cryotherapy. *Surv Ophthalmol* 1977;22:120-125.
 75. Devenyi RG, Mieler WF, Lambrou FH, Will BR, Aaberg TM. Cryopexy of the vitreous base in the management of peripheral uveitis. *Am J Ophthalmol* 1988;106:135-138.
 76. Mieler WF, Aaberg TM. Further observations on cryotherapy of the vitreous base in the management of peripheral uveitis. *Dev Ophthalmol* 1992;23:190-195.
 77. Franklin RM. Laser photocoagulation of retinal neovascularization in intermediate uveitis. *Dev Ophthalmol* 1992;23:251-260.
 78. Park SE, Mieler WF, Pulido JS. 2 peripheral scatter photocoagulation for neovascularization associated with pars planitis. *Arch Ophthalmol* 1995;113:1277-1280.
 79. Pulido JS, Mieler WF, Walton D, Kuhn E, Postel E, Hartz A, et al. Results of peripheral laser photocoagulation in pars planitis. *Trans Am Ophthalmol Soc* 1998;96:127-137.
 80. Ganesh SK, Babu K, Biswas J. Phacoemulsification with intraocular lens implantation in cases of pars planitis. *J Cataract Refract Surg* 2004;30:2072-2076.
 81. Kaufman AH, Foster CS. Cataract extraction in patients with pars planitis. *Ophthalmology* 1993;100:1210-1217.
 82. Smith RE, Godfrey WA, Kimura SJ. Chronic cyclitis. I. Course and visual prognosis. *Trans Am Acad Ophthalmol Otolaryngol* 1973;77:OP760-OP768.
 83. Zierhut M, Doycheva D, Biester S, Stübiger N, Kümmerle-Deschner J, Deuter C. Therapy of uveitis in children. *Int Ophthalmol Clin* 2008;48:131-152.